

PATIENT

Jasper Bettius

SPECIES

Canine

BREED

Terrier Mix

SEX

Male Neutered

AGE

13 years

WEIGHT

10lbs

INTERPRETED BY

Maggie Machen Lamy,
DVM, DACVIM
(Cardiology)

IMAGING PERFORMED BY

Potomac Mobile
Veterinary Ultrasound

HOSPITAL NAME

Banfield Sterling
Towncenter

REFERRING VET

Dr. Jarrett

PRESENTING CLINICAL SIGNS

History: Grade III/VI heart murmur, left systolic. First ausculted in the past month. Asymptomatic, no concerns from client. Assess prior to dental.

-Abnormal PE/Chem/CBC/UA Results: NSF, 4dx: negative.

RADIOGRAPHIC FINDINGS *NOTE: Images submitted for supplemental cardiac information only.
Mild right-sided cardiomegaly with increased sternal contact. No obvious evidence of CHF.

ECHOCARDIOGRAM FINDINGS

2D, m-mode, color flow and doppler imaging is available. Mild diffuse thickening of mitral valve leaflets with no prolapse into the left atrial lumen. Mild eccentric mitral regurgitation with no left atrial dilation. Normal MR velocity. Normal LV diameter with adequate myocardial function. The tricuspid valve appears thickened with septal prolapse and moderate tricuspid regurgitation. Velocity consistent with mild pulmonary hypertension. Mild right atrial and ventricular enlargement consistent with pulmonary arterial hypertension. The pulmonic and aortic valves are normal in morphology and mobility. Normal pulmonic and aortic outflow velocities with laminar flow. No obvious aortic and mild pulmonic insufficiency. Mild MPA and branch dilation. No pericardial or pleural effusion noted. No obvious cardiac masses.

CARDIAC CHART

CANINE CARDIAC PARAMETERS	MR VMAX (m/s)	TR VMAX (m/s)	LA/AO (Boon method)	LA/AO (Heart Base; Swe)	FS (%)	EF (%)	EPSS (cm)
NORMAL PARAMETER	4.5-5.5	<2.7	1.3	<1.6	28-40	40-100	<0.6
PATIENT	5.9	3.2	1.3	1.3	42	75	0.2
CANINE CARDIAC PARAMETERS	HR (BPM)	AV VMAX (m/s)	PV MAX (m/s)	BODY WEIGHT (kg)	LA 2D short axis Base view (cm)	LVIDd Avg; 2D and m-mode short axis (cm)	LVIDs Avg; 2D and m-mode short axis (cm)
NORMAL PARAMETER	50-100	0.7-1.7	0.7-1.6	BELOW	BELOW	BELOW	BELOW
PATIENT	94	1.6	1.2	4.5	1.6	2.5	1.5
*Normal chamber parameters expressed as a mean value (SD)				3	1.27 (5.3)	2.46 (2.46)	1.36 (5.5)
BODY WEIGHT DEPENDENT PARAMETERS				5	1.40 (4.5)	2.74 (5.2)	1.60 (4.7)
<i>*Note: All measurements based upon multi-modal images and methods. An average value is reported.</i>				10	1.50 (3.8)	3.27 (3.5)	2.06 (3.1)
				15	1.83 (2.0)	3.71 (2.4)	2.43 (2.1)
				20	2.02 (1.9)	4.14 (2.2)	2.80 (2.0)
				25	2.18 (2.4)	4.48 (2.9)	3.10 (2.5)
				30	2.33 (3.3)	4.83 (3.9)	3.39 (3.4)
				35	2.48 (4.3)	5.17 (5.0)	3.69 (4.5)
				40	2.62 (5.2)	5.48 (6.1)	3.96 (5.4)
				50	2.88 (7.1)	6.07 (8.3)	4.46 (7.4)

INTERPRETATION OF THE FINDINGS & FURTHER RECOMMENDATIONS

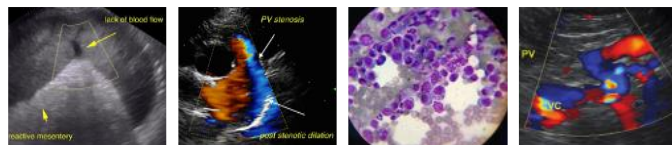
Chronic degenerative valve disease causing mild mitral and moderate tricuspid regurgitation. Lack of significant left atrial enlargement indicates the current risk for complication is low. Mild pulmonary hypertension is noted which should be monitored going forward in this predisposed

INVOICE

21651

DATE

10/21/21



PATIENT

Jasper Bettius

breed. The right heart is mildly enlarged indicating relatively low risk for complication at this time. No additional issues are noted in this study.

SPECIES

Canine

Given these findings, no cardiac medications are clearly indicated. PAH typically develops secondary to chronic respiratory signs that are not noted in this case. Primary PAH is also a possible and may result in exertional dyspnea or syncope, monitoring for clinical signs at home is recommended. Assessment of progression in the future will help predict long term prognosis, which is highly variable at this stage (B1). Omega fatty acid supplementation and mild salt restriction may be of some long-term benefit. Monitor for development of a cough, labored breathing, exercise intolerance or collapse episodes.

BREED

Terrier Mix

SEX

Male Neutered

Anesthetic risk is considered mild if needed. Cardiac protective drug choices (opioid/benzodiazepine premedication, propofol or alfaxalone induction, isoflurane gas) are recommended. **Pre-oxygenate for 5-10 minutes prior to induction.** Monitor for arrhythmias, hypotension, and hypoxia both intra and post-operatively and intervene as necessary. Mild IV fluid restriction is recommended to avoid fluid overload. Avoid heart rate stimulating drugs such as atropine unless clinically indicated.

AGE

13 years

Recommend conservative monitoring with a recheck echocardiogram in 6 months, sooner if any development of clinical signs.

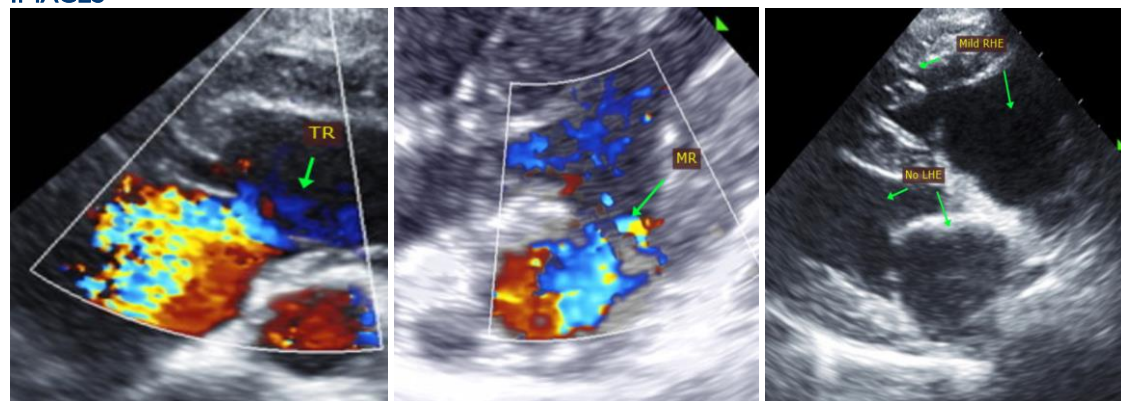
WEIGHT

10lbs

IMAGES

INTERPRETED BY

Maggie Machen Lamy,
DVM, DACVIM
(Cardiology)



IMAGING PERFORMED BY

Potomac Mobile
Veterinary Ultrasound

HOSPITAL NAME

Banfield Sterling
Towncenter

The information and recommendations provided are based on the images presented by the referring veterinarian. No evaluation can be communicated regarding pathology that was not visible in the image/video clips provided.

REFERRING VET

Dr. Jarrett

Thank you for this referral. This report was generated using transcription software, and minor dictation errors may be present. If the clinical or image interpretation does not parallel your findings or if I can be of any further assistance, please contact me.

INVOICE

21651

Maggie Machen Lamy, DVM
Diplomate of the American College of Veterinary Internal Medicine (Cardiology)
info@sonopath.com

DATE

10/21/21